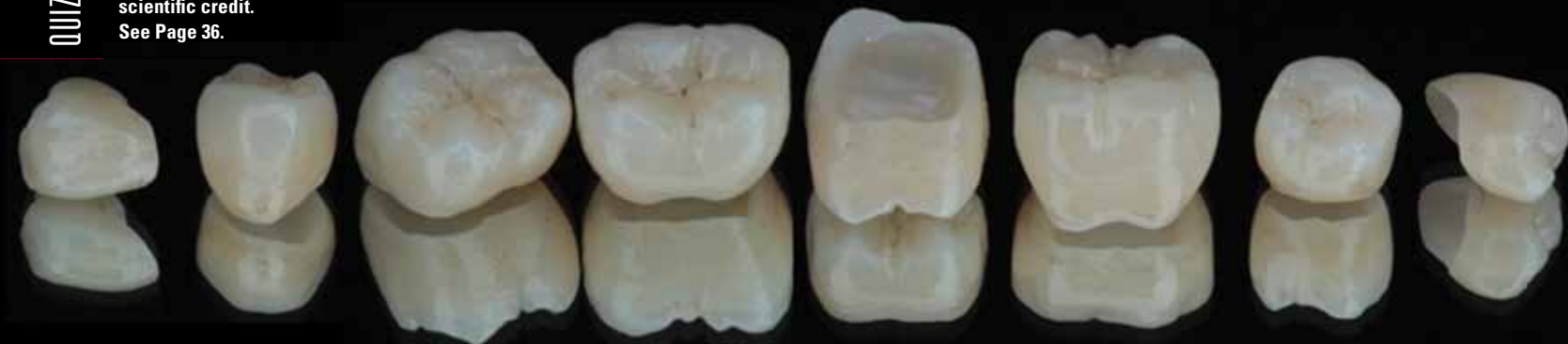



By Lucas T. Lammott*, and Miles R. Cone, DMD, CDT **

Rehabilitation of Erosive Tooth Surface Loss in a Patient Diagnosed with Bruxism, Utilizing CAD/CAM Technology and a Monolithic Multi-layered Zirconia

RESTORATION
OF A SEVERELY
ERODED
DENTITION
REQUIRES
CAREFUL
DIAGNOSIS,
TREATMENT
PLANNING AND
COLLABORATION.

Abstract

The etiology of tooth surface loss (TSL) is a multifactorial phenomenon that affects many individuals seeking rehabilitative dental treatment. Patients often present with parafunctional habits, such as bruxism, coupled with intrinsic variables such as highly abrasive antagonistic restorations. Pathological TSL has the potential to negatively impact a patient's quality of life in regards to both function and aesthetics. The integration of CAD/CAM digital technology and the utilization of full-contoured anatomical zirconia crowns as a part of the comprehensive treatment plan for these patients allows for the delivery of predictable, minimally invasive all-ceramic restorations with a favorable long-term prognosis.

Introduction

Tooth wear may result from various processes, including abrasion (an abnormal wearing away of the tooth substance by causes other than mastication), attrition (the mechanical wear resulting from mastication or parafunction, limited to contacting surfaces of the teeth) and lastly, erosion (the progressive loss of tooth substance by chemical processes that do not involve bacterial action)^{1,2}. These mechanisms frequently act in concert with one another and they are well-regarded as naturally occurring lifelong processes that occur at a predictable rate of approximately 20-40 μ /year, and often require little or no treatment^{3,4}. When these baseline values are severely accelerated, however, the diagnosis of tooth wear turns from physiological to pathological⁵. Pathological tooth surface loss is a

* Owner, M31 Dental Studio / Director of Dental Technology, Custom Automated Prosthetics, Stoneham, Mass.;

** Owner, Nuance Dental Specialists, Portland, Maine

worldwide phenomenon of increasing significance⁶ and the rehabilitation of a severely worn dentition constitutes one of the most challenging and complex procedures that today's restorative dental team faces⁷. Patient clinical presentation of non-carious erosive tooth wear typically includes salient changes in tooth morphology, loss of anterior guidance⁸, compromised masticatory function⁹, collapsed occlusal vertical dimension, dentoalveolar compensation¹⁰, pulpal complications, and poor aesthetics¹¹. Factors which when combined have an interplay on the patient's overall quality of life¹². Restoration of a severely eroded dentition is largely dictated by individual circumstances and requires careful diagnosis, treatment planning and collaboration on the part of the restorative dentist and auxiliary dental team, including other dental specialists and the laboratory technician.

Case Presentation/ Patient Evaluation

The patient is a 68-year old Caucasian male (Fig. 1) in good overall health who presented with a chief complaint of wanting to enhance the aesthetics and function of his severely worn mandibular dentition (Figs. 2-3). A comprehensive extra-oral, intra-oral and radiographic examination (Fig. 4) reveals a fully restored maxilla (teeth #2-#15) comprised of splinted individual metal-ceramic crowns (MCCs) and metal-ceramic fixed dental prostheses (MCFDPs). Numerous posterior mandibular teeth have been restored with

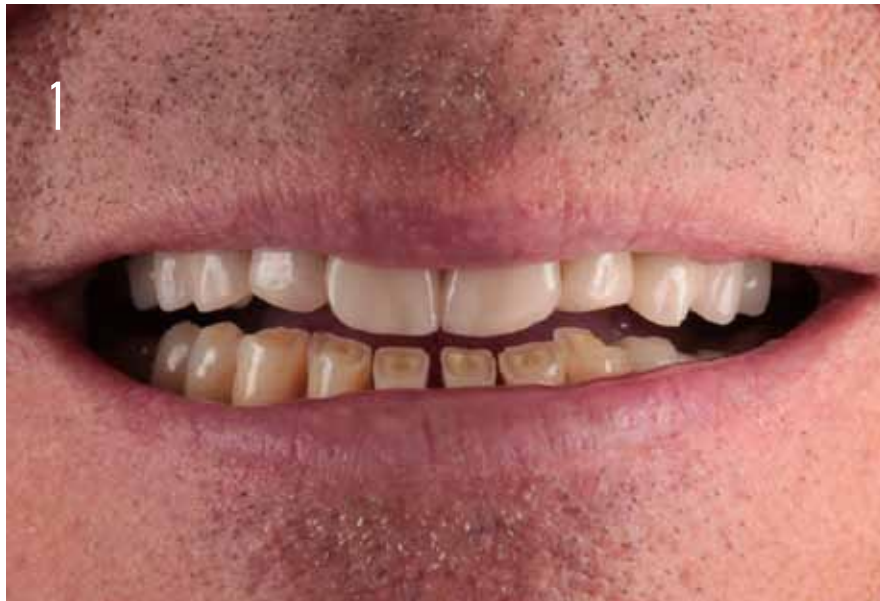

Figure 1-2

Initial patient presentation. Mandibular anterior dentition displays evidence of erosive tooth surface loss.

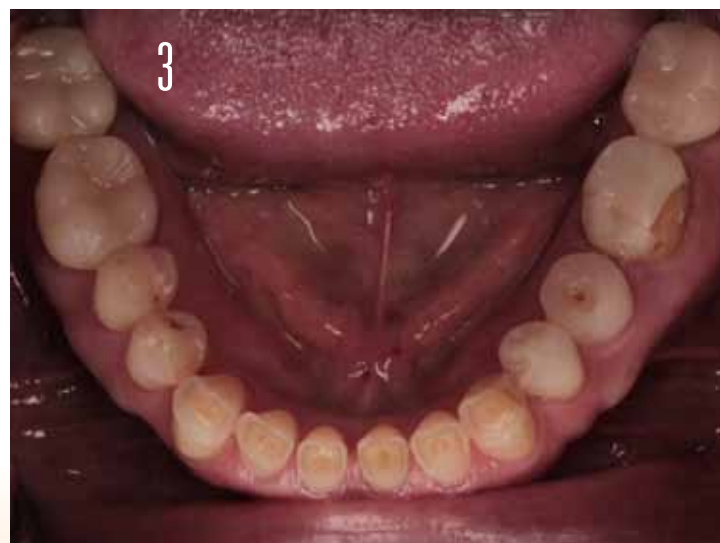
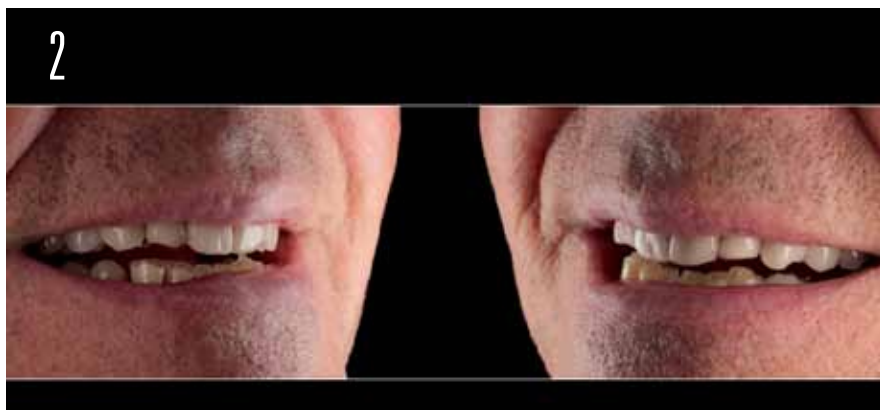

Figure 3

Occlusal view of mandibular arch revealing fracture of definitive restoration (tooth #19) and aggressive generalized erosive wear (teeth #20 - #29).

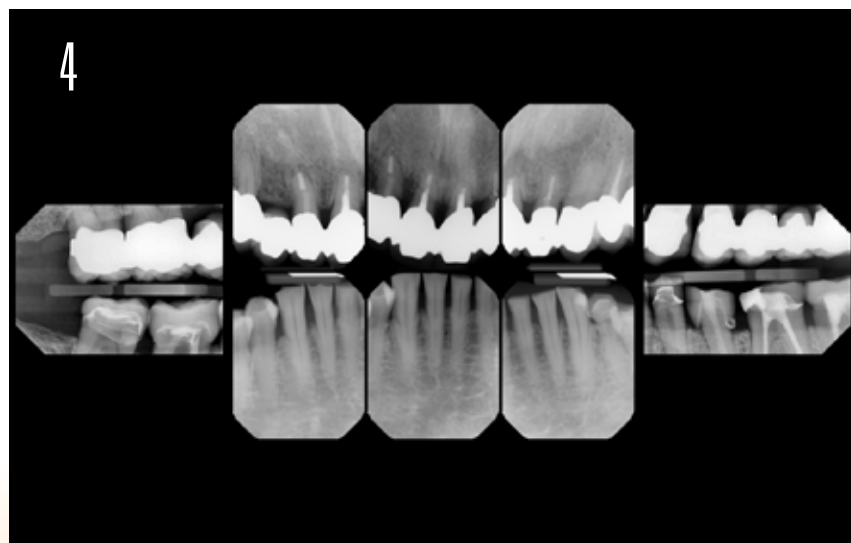

Figure 4

Radiographic evaluation revealing complete maxillary arch restoration with metal-ceramic crowns and existing lithium disilicate crowns on mandibular posterior dentition (teeth #18-#21, #30, and #31).

full-contour monolithic lithium disilicate crowns (teeth #18-#21, #30, #31) and show signs of wear and material fracture (Fig. 5). The mandibular anterior dentition is unrestored and shows evidence of progressive, long-standing erosion resulting from nocturnal bruxism in conjunction with highly abrasive antagonistic ceramic crowns in the maxillary arch (Fig. 6).

Figure 5

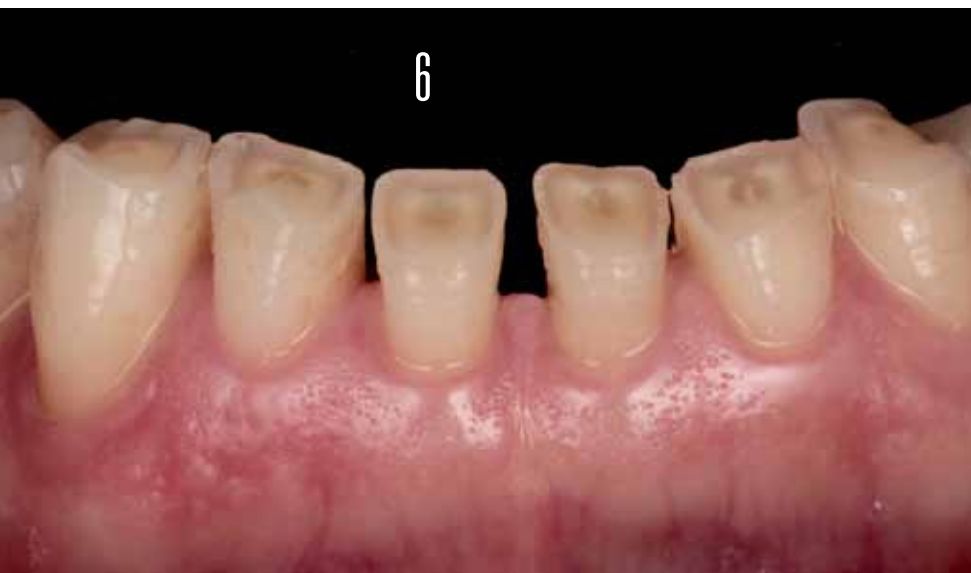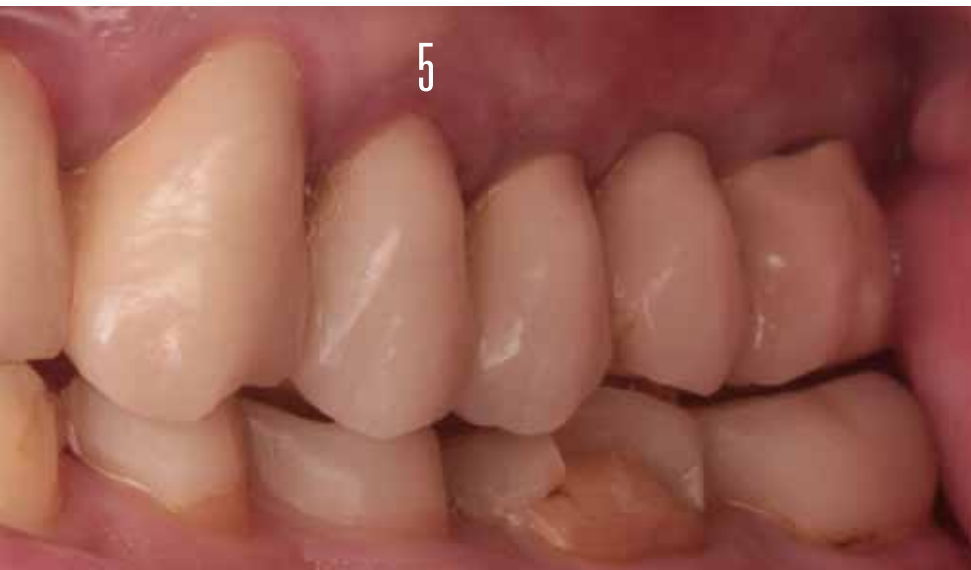Figure 6

Unrestored mandibular arch exhibiting dentoalveolar compensatory eruption and severe incisofacial wear from unpolished antagonistic metal-ceramic restorations.

The patient's occlusal vertical dimension (OVD) and vertical dimension at rest (VDR) were assessed by means of a phonetic evaluation¹³, and the inter-occlusal space at rest¹⁴ was evaluated utilizing Niswonger's technique¹⁵. A centric occlusion (CO) jaw position was established utilizing chin point guidance¹⁶ and an inter-occlusal bite registration was fabricated at this position utilizing a fast-set vinyl polysiloxane¹⁷.

It was noted at the time of the initial examination that the gingival apices of the mandibular incisors and lower left canine were uneven with the adjacent teeth – a pathognomonic hallmark of continuous compensatory eruption of the alveolus and associated dentition^{18,19}. The concomitant breakdown and gradual eruption of worn tooth structure frequently results in a well-maintained OVD, however, treating patients such as this is often met with challenges as a result of the limited inter-occlusal space available to accommodate the restorative materials necessary to complete an oral rehabilitation²⁰.

After the initial diagnostic appointment, irreversible hydrocolloid impressions were made of the maxillary and mandibular arches. These casts were poured in a type IV die stone, duplicated in silicone and subsequently mounted on a semi-adjustable articulator utilizing the face-bow transfer record and previously fabricated inter-occlusal bite registration. Mounting of the diagnostic casts revealed that the patient's centric occlusion and maximum intercuspal position were coincident. The mounted casts further validated the initial concerns regarding the lack of space for materials required to appropriately restore the anterior dentition. For patients who seek treatment of the sequelae resulting from severe dental erosion, it is often a necessity to increase the existing OVD. Raising the vertical dimension typically requires the restoration of most if not all teeth in at least one arch in order to re-establish contact with the antagonistic dentition. Addressing the patient's chief complaint in this instance only required the placement of restorations in the mandible since his maxillary MCCs were functional and not an aesthetic concern. A diagnostic wax up of teeth #18 through #31 was completed in the laboratory and individual quadrant / sextant silicone (type 0) matrices were then fabricated to serve as tooth preparation reduction guides and as templates for the fabrication of provisional restorations. Increasing the OVD was once thought to be an ill-advised endeavor, however, contemporary treatment planning strategies in which the OVD is increased by as much as 5mm in dentate patients has been shown to be well-tolerated²¹. Three clinical situations in which it may be advised to alter the OVD include: 1) obtaining inter-occlusal clearance for restorative materials, 2) enhancing aesthetic treatment outcomes, and 3) correction of unfavorable occlusal situations (e.g., increasing the OVD in a class III occlusal relationship to obtain a class I occlusal relationship)⁷.



Treatment Protocol

There are currently no evidenced-based standardized protocols in place to guide clinicians in the comprehensive restoration of a severely worn and eroded dentition¹¹. Sensible generalized guidelines for therapy, however, should include at a minimum a review of the patient's dietary history, observed para-functional habits²², and consideration of a minimally invasive treatment strategy involving restorative materials that possesses both strength and aesthetics.

Material Selection

Material selection for erosive wear cases involves a mutual dialogue between the clinician and the ceramist. This collaboration between the chair and the bench is paramount to a successful and predictable result and must preclude any irreversible treatment. It was determined that for this particular patient a 3mm increase in the OVD in the anterior region (=1mm at the second molar) was essential to the goal of realizing a restoration that would be both bio-mechanically stable and would simultaneously satisfy the patient's cosmetic desires.

The application of composite resin for cases involving tooth surface loss has merit as a suitable medium-term restorative material and indeed composite possesses several advantages: it is economical, minimally invasive and easy to repair. Disadvantages of resin-based materials, on the other hand, include an accelerated rate of wear that is approximately 3-4 times that of ceramic or cast metal alloys²³, marginal fracture and surface roughness²⁴.

In patient cases that involve extensive erosion and restoration failure due to parafunctional habits, it becomes necessary utilize a stronger material to ensure a favorable long-term prognosis. Since the introduction of zirconia into the dental field in the early 1990's²⁵, the application of this ceramic has been shown to be an excellent material of choice for patients who exhibit bruxism²⁶. Utilizing rapidly evolving CAD/

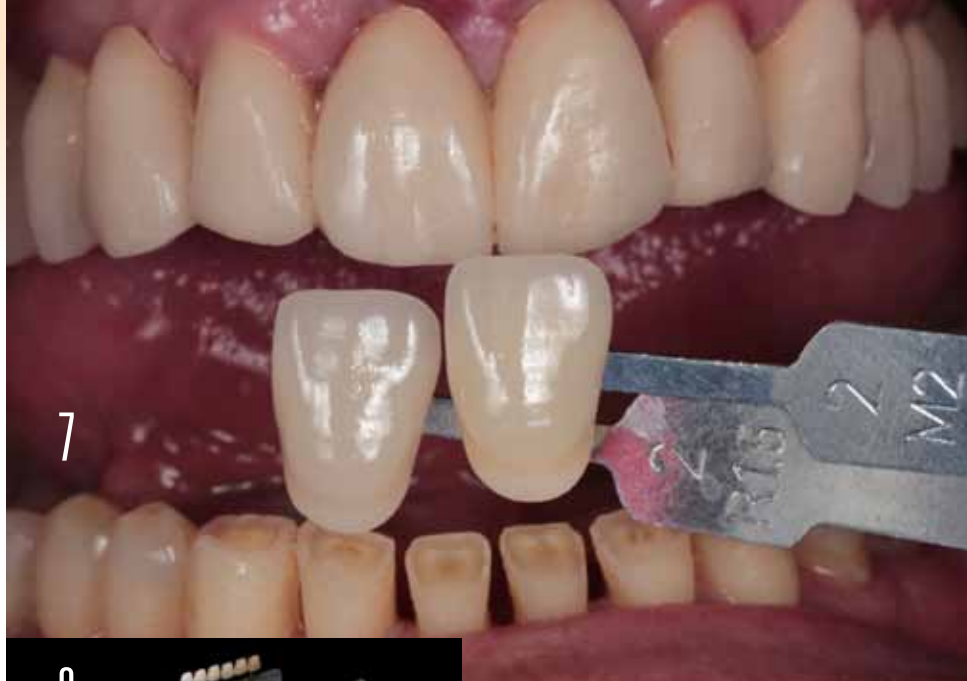

Figure 7
Tooth shade analysis using the Vita Linearguide 3D Master.




Figure 8
Vita Linearguide 3D Master shade guide.

CAM digital technology, the ability to manufacture fully anatomic monolithic zirconia restorations has become both predictable, efficient and economical²⁷. The high-strength of monolithic zirconia restorations allows for tooth preparations similar to those for cast metal alloys, with a minimum occlusal and axial reduction of 0.5-0.7mm and 0.5mm, respectively. These conservative preparation guidelines potentially reduce the risk of untoward biological complications, such as endodontic therapy^{28,29,30}. Issues with the intense opacity of zirconia have now been overcome as a result of our growing understanding of the optical properties of this material. Available options for zirconia now include super high translucent (SHT) cubic zirconia discs and blocks which possess a multilayered (ML) technology which are capable of reproducing highly aesthetic multicolored dentin and enamel without the use of external surface stains³¹. This high-strength, highly aesthetic zirconia was the obvious material of choice selected for this rehabilitation.

Tooth Preparation/ Final Impressions/ Provisionalization

Prior to tooth preparation, crown lengthening was performed for all teeth in the mandibular arch in order to aid resistance and retention form (posterior quadrants, bilaterally) and to enhance aesthetics (anterior sextant). Following a 16-week healing and tissue maturation period, new diagnostic alginate impressions were made and the existing wax-up was transferred to each cast. A type 0 silicone matrix was fabricated from the new wax-up and utilized intra-orally to create a bis-acryl provisional mock-up of each posterior quadrant as a means of creating the proposed increase in OVD. Immediately prior to tooth preparation, shade selection was performed (Fig. 7) and photographically documented utilizing the Vita Linearguide 3D Master (Fig. 8).

The anterior sextant was prepared first, employing a minimally invasive

Figure 9

3Shape tooth preparation scan images showcasing the Nondas anatomical library for the mandibular anterior sextant.

Figure 10

3Shape scan images being utilized to contour and adjust occlusal anatomy of mandibular left quadrant.

0.5mm shoulder preparation circumferentially and limiting the incisal reduction to rounding off existing sharp line angles while preserving vertical height of the clinical crown. A two cord technique was utilized to achieve adequate isolation for the six anterior tooth preparations during impression making. A stock tray loaded with a monophasic VPS as well as a low-viscosity VPS wash was used for the final impressions. Immediately following the final impression, a VPS bite registration

was made of the prepared teeth (#22-#26 only) and these teeth were then provisionalized and splinted together with a bis-acryl temporary material. The new provisionals were then utilized to maintain the increased OVD and the posterior quadrants were prepared and provisionalized in a similar manner. All photographs, diagnostic casts, bite-registration and final impressions were delivered to the laboratory for fabrication of the definitive restorations.

Laboratory Phase

The final impressions were poured in a type IV resin-reinforced die stone and mounted on the Artex CR semi-adjustable articulator. Tooth preparations were then scanned in the 3Shape D2000 and designed with the Nondas anatomy library (Fig. 9). Occlusion was carried out within the 3Shape digital platform prior to milling (Fig. 10). Amann Girrbach's Zolid FX Multi Layered zirconia, shade A2/A3, was selected based on pre-operative shade photographs and milled as a full-contour monolithic restoration. After milling was complete, the individual restorations were finished and macro anatomical contouring was completed in the pre-sintered state using the Green State Finishing kit from Wagner Rotary. The sintering process was completed using the Amann Girrbach Ceramill Therm 3. Upon completion of the sintering cycle, a final contour check and adjustments were performed with a Wagner Rotary "Blueberry" contouring wheel, followed by a Diacool 403 tapered barrel and an HE Silicone Wheel.

The stain and glaze process was completed with an initial stain and glaze combination bake using a variety of GC Lustre Pastes, including L-N, L-A, L-2 and INsitu ISB stains. The second bake was used for the final stain and glaze process using the above mentioned stains to complete the final touches (Fig. 11). After a final evaluation of contour, occlusal morphology, occlusion, and inter proximal contacts was performed, the restorations were polished using Wagner Rotary Calais ZR polishing compound. The intaglio surface of each restoration was subsequently particle abraded at 2.5 p.s.i. with a 50µ alumina oxide and subsequently returned to the dental clinic for delivery to the patient.

Delivery Sequencing

At the delivery appointment, all anterior provisional restorations were removed and the tooth preparations cleaned with a low abrasive pumice and oral rinse solution. Each restoration was seated

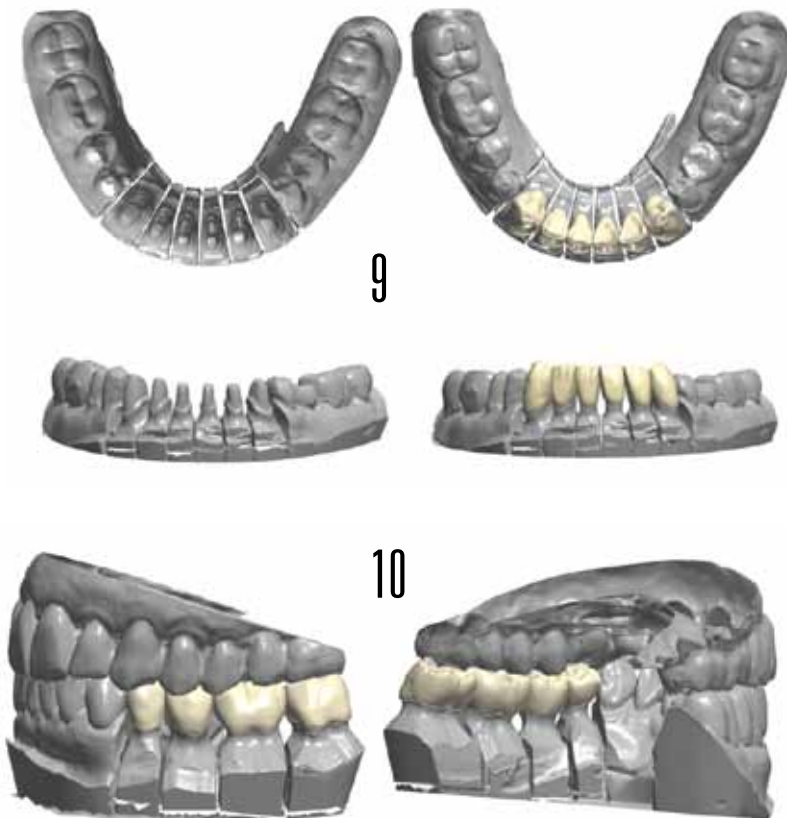
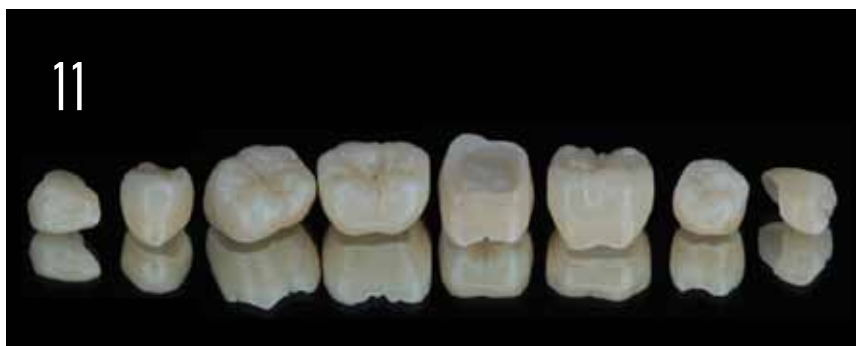

Figure 11

Amann Girrbach Zolid Multilayer FX monolithic zirconia restorations.



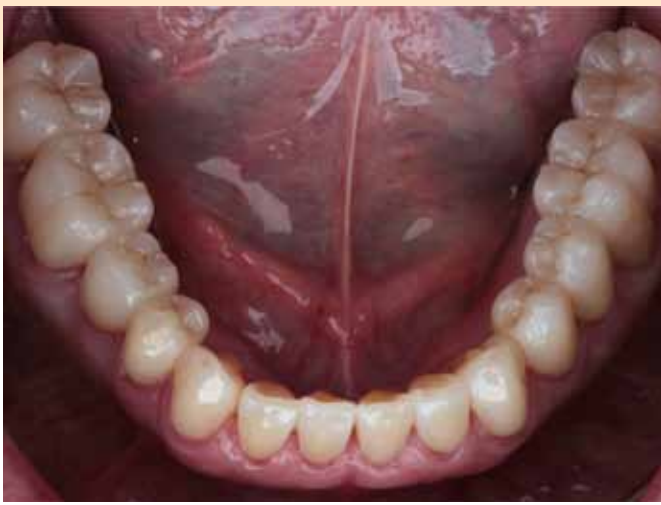

Figure 12

Occlusal view of complete mandibular arch rehabilitation with the application of super high translucency fully anatomic monolithic zirconia restorations.

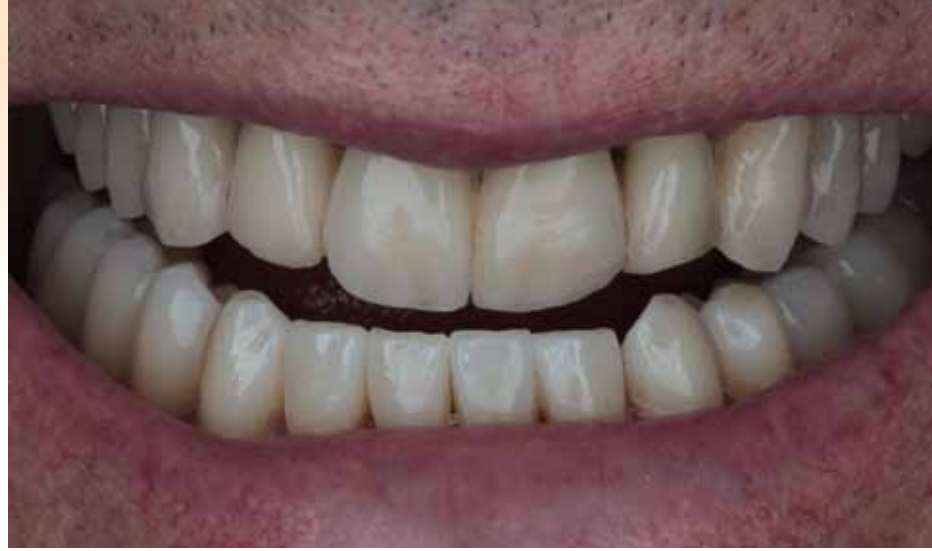

Figure 13

Anterior view of completed patient treatment demonstrating the harmonious blend of multilayered zirconia crowns (mandible) with feldspathic metal-ceramic crowns (maxilla).

individually and evaluated for strength of interproximal contacts and occlusion utilizing 21 μ Accufilm II articulating paper. Upon patient approval of aesthetics, each crown was luted one at a time with a resin-modified glass ionomer cement (GC FujiCEM 2) and cured with a 405nm light source for 60 seconds. All excess cement was cleaned from the margins and occlusion and contacts were re-evaluated prior to patient dismissal. At the one week post-operative follow-up visit, a full-arch impression of the left quadrant was made (teeth #28-#31). This sequence was repeated for the remaining right quadrant (teeth #18-#21), following delivery of the definitive restorations for #28-#31 (**Fig. 12**). Treatment planning in this manner allowed for greater control of the impression making process and development of the occlusal scheme in the laboratory, ultimately concluding with a successful aesthetic and functional final result that the patient was extremely satisfied with (**Fig. 13**).

Conclusion

For patients that exhibit severe tooth surface loss, with or without a collapse of OVD, full-coverage restorations that cover at least one arch are frequently inevitable. The incorporation of CAD/CAM technology and the utilization of highly translucent monolithic cubic zirconia crowns for patients with erosive

wear have proven to be an effective, aesthetic and conservative means of oral rehabilitation when treating these complex cases. A thorough understanding of the etiology of the erosive lesions is critical for each case in order to end the disease process. Additionally, continued recall and oral hygiene visits are recommended for these patients in order to safeguard their long-term well-being and functional oral health.

*The authors wish to extend their sincere appreciation to Custom Automated Prosthetics (C.A.P.) for the contribution of their world class scanning and milling facilities, and a special acknowledgement of gratitude to Carrie-Ann Cokely CDT, for her expert skill that went into the digital workflow and design of this complex case. **JDT**

References

1. Addy M, Shellis RP. Interaction between attrition, abrasion and erosion in tooth wear. *Monogr Oral Sci.* 2006;20:17-31.
2. Glossary of Prosthodontic Terms. 8th ed. *J Prosthet Dent.* 2005;(94)1:10-92.
3. Lambrechts P, Braem M, Vanherle G. Buonocore memorial lecture. Evaluation of clinical performance for posterior composite resins and dentin adhesives. *Oper Dent.* 1987;12(2):53-78.
4. Lambrechts P, Braem M, Vuylsteke-Wauters M, et al. Quantitative in vivo wear of human enamel. *J Dent Res.* 1989;68(12):1752-4.
5. Verrett RG. Analyzing the etiology of an extremely worn dentition. *J Prosthodont.* 2001;10(4):224-33.
6. Jaeggi T, Lussi A. Prevalence, incidence and distribution of erosion. *Monogr Oral Sci.* 2006;20:44-65.
7. Lerner J. A systematic approach to full-mouth reconstruction of the severely worn dentition. *Prac Proced Aesthet Dent.* 2008;20(2):81-7.
8. Dietschi D, Argente A. A comprehensive and conservative approach for the restoration of abrasion and erosion. Part 1: concepts and clinical rationale for early intervention using adhesive techniques. *Eur J Esthet Dent.* 2011;6(1):20-33.
9. Mehta SB, Banerji S, Millar BJ, Suarez-Feito JM. Current concepts on the management of tooth wear. Part 1: assessment, treatment planning and strategies for the prevention and the passive management of tooth wear. *Br Dent J.* 2012;212(1):17-27.
10. Davies SJ, Gray RJM, Qualtrough AJE. Management of tooth surface loss. *Br Dent J.* 2002;192(1):11-23.
11. Muts EJ, van Pelt H, Edelhoff D, Krejci I, Cune M. Tooth wear: a systematic review of treatment options. *J Prosth Dent.* 2014;112(4):752-9.
12. Al-Omin MK, Lamey PJ, Clifford T. Impact of tooth wear on daily living. *Int J Prosthodont.* 2006;19(6):601-5.
13. Pound E. The mandibular movements of speech and their seven related values. *J Prosthet Dent.* 1966;16(5):835-43.

14. Silverman MM. The speaking method in measuring vertical dimension. *J Prosthet Dent.* 1953;3(2):193-9.
15. Niswonger ME. Rest position of the mandible and centric relation. *J Am Dent Assoc.* 1934;21(9):1572-82.
16. Lucia VO. Centric relation, theory and practice. *J Prosthet Dent.* 1960;10(5):849-55.
17. Breeding LC, Dixon DL. Compression resistance of four interocclusal recording materials. *J Prosthet Dent.* 1992;68(6):876-8.
18. Sisher H. *Oral Anatomy.* 5th ed. Mosby, St.Louis, MO: 1949:270
19. Zengingul S, Eskimez Y, Deger J, Kama J, et al. Tooth wears and dentoalveolar compensation of vertical height. *Biotechnology & Biotechnology Equipment.* 2007;21(3):362-5.
20. Turner KA, Missirlian DM. Restoration of the extremely worn dentition. *J Prosthet Dent.* 1984;52(4):467-74.
21. Abudo J. Safety of increase the VDO: a review. *Quintessence Int.* 2012;43:369-80.
22. Neff P. Trauma from occlusion. Restorative concerns. *Dent Clin North Am.* 1995;39(2):335-54.
23. Dahl B, Oilo G. Wear of teeth and restorative material. In: Kayser AF, Carlsson GE, eds. *Prosthodontics principles and management strategies:* Mosby-Wolfe, London: 1996:187-200.
24. Redman CD, Hemmings KW, Good JA. The survival and clinical performance of resin-based composite restorations used to treat localised anterior tooth wear. *Br Dent J.* 2003;194(10):566-72.
25. Conrad HJ, Seong WJ, Pesun IJ. Current ceramic materials and systems with clinical recommendations: a systematic review. *J Prosthet Dent.* 2007;(98(5):389-404.
26. Höland W, Schweiger M, Watzke R, Peschke A, Kappert H. Ceramics as biomaterials for dental restoration. *Expert Rev Med Devices.* 2008;5(6):729-45.
27. Zarone F, Russo S, Sorrentino R. From porcelain-fused-to-metal to zirconia: clinical and experimental considerations. *Dent Mater.* 2011;27(1):83-96.
28. Rinke S, Fischer C. Range of indications for translucent zirconia modifications: clinical and technical aspects. *Quintessence Int.* 2013;44(8):557-66.
29. Kim HK, Kim SH, Lee JB, Han JS, Yeo IS. Application of monolithic zirconia ceramics in dental practice: a case history report. *Int J Prosthodont.* 2016;29(5):511-3.
30. Stober T, Bermejo JL, Rammelsberg P, Schmitter M. Enamel wear caused by monolithic zirconia crowns after 6 months of use. *J Oral Rehabil.* 2014;41(4):314-22.
31. Rondoni D. Zirconia: some practical aspects from the technologist's point of view. *Int J Esthet Dent.* 2016;11(2):270-4.
32. Clary JA, Ontiveros JC, Cron SG, Paravina RD. Influence of light source, polarization, education, and training on shade matching quality. *J Prosthet Dent.* 2016;116(1):91-7.

About the Authors



Dr. Miles R. Cone is a graduate of Tufts University School of Dental Medicine, and completed a three-year Prosthodontic residency program while serving in the United States Army before being honorably discharged as a field grade

officer in the rank of Major. In addition to achieving board certification and diplomate status within his specialty, Miles has also successfully challenged all the requirements necessary to earn his designation as a Certified Dental Technician. Currently Miles' career in civilian life revolves around his dual role as the owner of Nuance Dental Specialists, a private practice dental clinic limited to prosthetic dentistry in the heart of Portland, Maine, and his faculty position at the University of New England College of Dental Medicine. When Miles is not at the chair in the classroom or at the bench, he serves as a Key Opinion Leader and guest speaker for Amann Girschbach, GC America, and Straumann.



Lucas Theron Lammott began his career in dental artistry at the age of seventeen, when he apprenticed under Master technician, Charles Upham. After working in several labs across the country, in 2014, Lucas committed to opening

his own lab, which he named M31 Dental Studio, after his daughter, Andromeda. Lucas fulfills an additional laboratory role as the "Director of Custom Aesthetics" at Advanced Dental Technologies. Academically, Lucas' techniques and knowledge have been featured in numerous peer-reviewed publications including the *Journal of Cosmetic Dentistry*, the *Journal of Dental Technology* and the *Journal of Prosthetic Dentistry*. Lucas is a KOL (Key Opinion Leader) for GC America, Amann Girschbach and Wagner Rotary.

Receive .5 point documented scientific credit for passing a quiz about this article. To get the quiz go to www.nadl.org/jdt. You can enter your answers to this quiz (course code #?????) at www.nadl.org/members/JDT/quizzes/index.cfm or fax the completed quiz to (850) 222-0053. This quiz is provided to test the technician's comprehension of the article's content and does not necessarily serve as an endorsement of the content by NADL or NBC.

